

# <CLINICAL>Clinical results of vital tooth bleaching : 1. In-office bleaching

著者名(英)	SAITO, Takashi / IBARAKI, Yuji / KAWAKAMI, Tomofumi / MATSUDA, Koichi
journal or publication title	東日本歯学雑誌
volume	22
number	1
page range	51-56
year	2003-06-30
URL	<a href="http://id.nii.ac.jp/1145/00008779/">http://id.nii.ac.jp/1145/00008779/</a>

## [CLINICAL]

## Clinical results of vital tooth bleaching: 1. In-office bleaching

Takashi SAITO, Yuji IBARAKI, Tomofumi KAWAKAMI  
and Koichi MATSUDA

Department of Operative Dentistry and Endodontology,  
School of Dentistry, Health Sciences University of Hokkaido

(Chief : Prof. Hiroki OHNO)

### Abstract

In recent years, demand for esthetic dentistry has grown, particularly with respect to treatment of discolored anterior teeth. Tooth discoloration and pigmentation can be treated by polishing or bleaching the tooth, or by laminate veneering. Bleaching is widely used, since it allows esthetic restoration without removal of the tooth surface. However, its tooth-bleaching efficacy is often assessed in a subjective manner. This report describes the use of in-office bleaching of tetracycline-induced tooth discoloration and yellowed teeth using Hi-Lite™ and Power Gel™, respectively, and objective assessment of efficacy. In both cases, excellent improvement in tooth color was noted, with a color difference ( $\Delta E$ ) from baseline of 5.8-6.5. These results support that in-office bleaching using Hi-Lite™ or Power Gel™ is a safe and efficacious method for the treatment of tooth discoloration.

**Key words :** Tooth discoloration, In-office bleaching, Vital tooth bleaching, Color difference.

### Introduction

The number of patients requesting esthetic improvement of discolored teeth has increased in recent years, in line with recognition of the increasing importance of improved oral health and general appearance<sup>1)</sup>. One esthetic treatment of discolored teeth is “bleaching”, a technique which conserves tooth substance, and this method has been used extensively<sup>1-17)</sup>. Since 1988, when “Hi-Lite™” (Shofu Inc., Kyoto, Japan)<sup>3)</sup> was approved by the Ministry of Health, Welfare and Labor, Japan as a bleaching material for use on vital discolored tooth, interest in vital teeth

---

受付：平成15年3月24日

bleaching by both dentists and patients has been growing rapidly. This is in spite of the fact that this treatment is not covered by the national health insurance in Japan.

Here, we report two typical cases where in-office bleaching treatment was performed at the hospital of Health Sciences University of Hokkaido, School of Dentistry (Tobetsu, Hokkaido).

### Case-1

Patient : 21-year-old female

Chief complaint : Dissatisfaction with appearance of all teeth

Anamnesis : Long-term use of antibiotics during childhood

History of the present illness : Discoloration has been present since eruption of the permanent teeth. Discoloration was not observed in the deciduous teeth.

Present condition : All teeth exhibited brown discoloration (Fig. 1). A horizontal stripe was not observed on the tooth crown. The shade of the teeth was C-3, -4 (Fig. 2). No caries was evident, and all teeth were vital except for 41, where a hard resin veneer crown was present. Periodontal pocket probing depths were 2-3 mm on all teeth. Some supragingival calculus was visible on the lingual surface of the lower incisors.

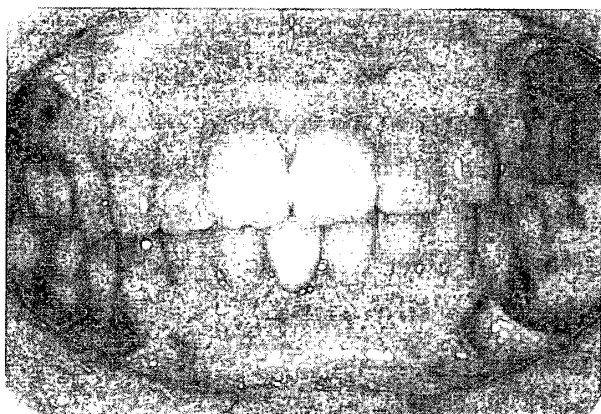


Fig. 1 Tetracycline-induced teeth discoloration

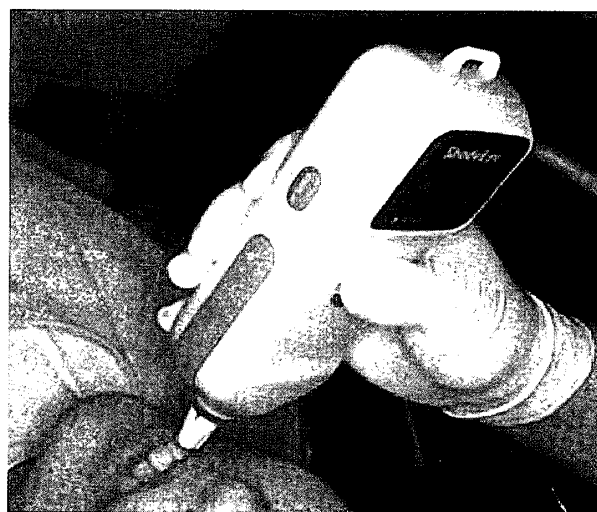


Fig. 2 Determination of tooth shade using Shade Eye™(Shofu Inc.)

Diagnosis : Tetracycline-induced tooth discoloration. Feinman Class II.

Treatment : Determination of tooth shade was performed using Shade Eye™ (Shofu Inc.) as shown in Fig. 2. After periodontal initial preparation, in-office bleaching of upper and lower anterior teeth was performed using Hi-Lite™ (Fig. 3). Briefly, tooth surface polishing was performed using polishing paste which does not include fluoride. Blue Vaseline (accessory of Hi-lite™) was applied to the marginal gingivae of the anterior teeth and a rubber dam was applied in order to provide a dry field and prevent injury to the oral soft tissues through leakage of hydrogen peroxide. Tooth bleaching was performed following the manufacturer's instructions (Fig. 4). An ARC Light™ II (Air Techniques Inc., Hicksville, NY, U.S.A.) was used as the

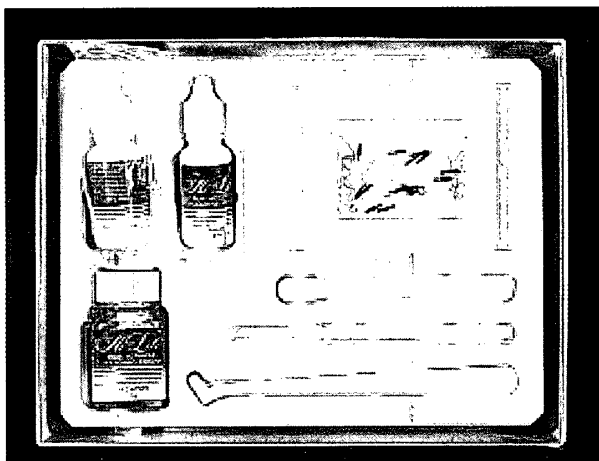


Fig. 3 Hi-Lite™(Shofu Inc.)



Fig. 4 Application of Hi-Lite™

visible light illuminator. The bleaching agent was applied three times per visit, and, in this case, a total of fifteen applications were performed. The patient did not report tooth hypersensitivity during the treatment period. The post-treatment shade of the anterior teeth was C-1 and -2 (Fig. 5). Following this treatment, professional mechanical tooth cleaning (PMTTC) and touch-up bleaching have been being performed at three to six month intervals. The shade of the teeth has been being maintained to be C-1 and -2.

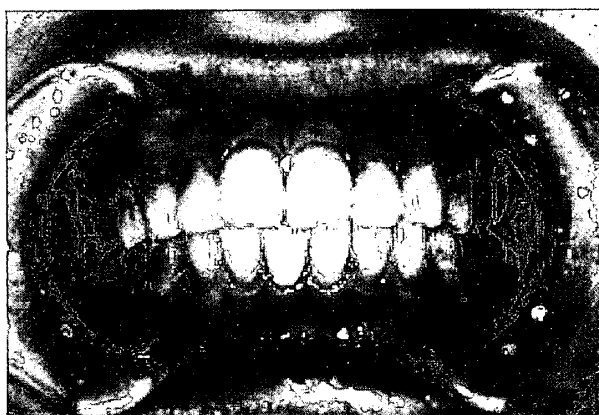


Fig. 5 Oral photograph after the bleaching using Hi-Lite™

## Case-2

Patient : 20-year-old female

Chief complaint : Dissatisfaction with appearance of 12 and 13

Anamnesis : The patient did not report long-term use of antibiotics or damage to the teeth in childhood, or bruise of the teeth.

History of the present illness : The patient had been concerned with the discoloration of 12 and 13 for the past three years.

Present condition : 12 and 13 exhibited yellow discoloration (Fig. 6). The shade of these teeth was B-3, compared with A-1 for the other anterior teeth. 12 and 13 were vital, and caries-free. Periodontal pocket probing depths were 1-2 mm on these teeth.

Diagnosis : Discoloration of unknown cause

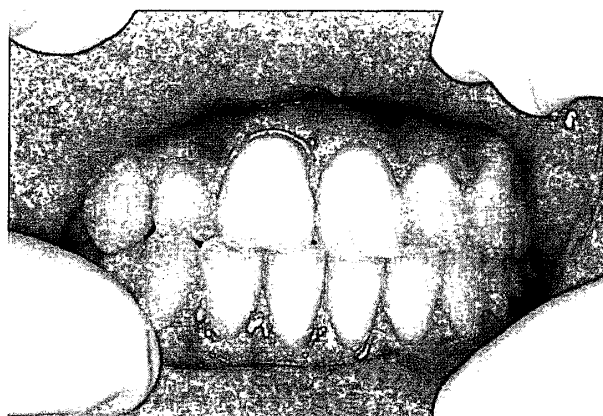


Fig. 6 Yellow discoloration in 12 and 13




Fig. 7 Power Gel™(WelchAllyn Kreativ)

Treatment : Initially, tooth cleaning was performed using a Robinson brush with polishing paste after tooth brushing instruction. Color improvement of 12 and 13 was not achieved, and so in-office bleaching was performed using Power Gel™ (WelchAllyn Kreativ, Skaneateles Falls, NY, U.S.A.) (Fig. 7). The marginal gingivae of 12 and 13 were protected using Gum Dam™ (Spectrum Dental Inc., Culver City, CA, U.S.A.) (Fig. 8), and tooth bleaching was performed following the manufacturer's instructions (Fig. 9). Two agent applications in one visit were given in this case. The patient did not report hypersensitivity of the treated teeth. The post-treatment shade of 12 and 13 was A-2 (Fig. 10). After this treatment, professional mechanical tooth cleaning (PMTTC) has been performed at six-month intervals. The shade of the teeth has been being maintained to be A-2.

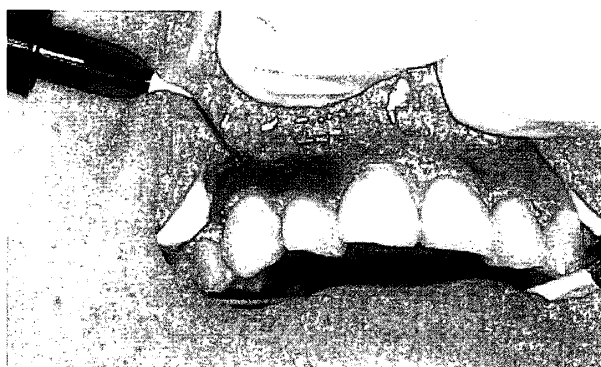


Fig. 8 Application of Gum Dam™ onto marginal gingivae (Spectrum Dental Inc.)

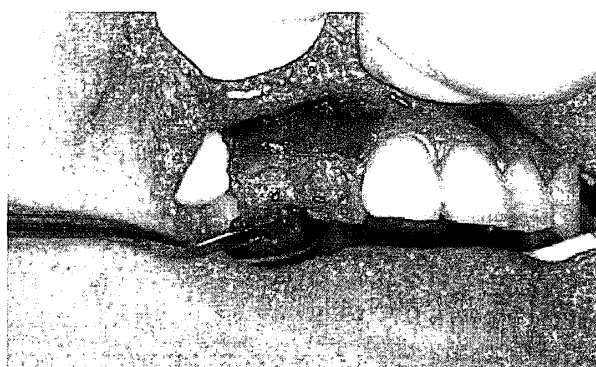

Fig. 9 Application of Power Gel™

## Discussion

Tooth whitening of discolored vital teeth may be performed in the office<sup>4,12-14</sup> or at home<sup>5-14</sup>. In-office bleaching has the advantage of being potentially safer, but does involve more time commitment from the patient. In the present clinical report, we used an in-office bleaching technique, using Hi-Lite™ and Power Gel™, to treat tetracycline-discolored teeth (Case-1) and

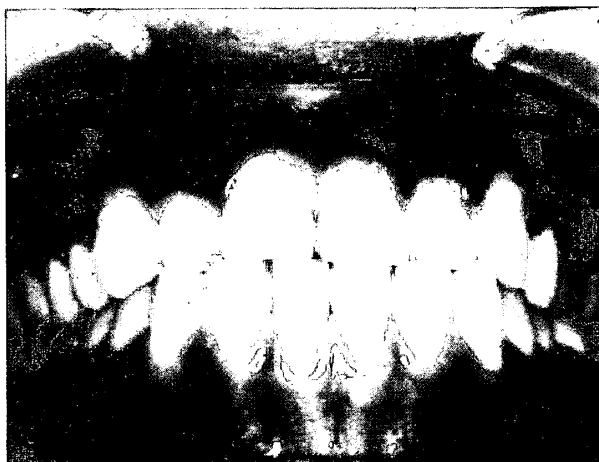

Fig.10 Oral photograph after the bleaching using Power Gel™

yellowed teeth (Case-2).

Both Hi-Lite™ and Power Gel™ are dual-activated bleaching system. Using these systems, free radicals are produced by degradation of hydrogen peroxide following exposure to visible light. The free radicals destroy the molecules responsible for discoloration as well as enamel matrices<sup>18)</sup>. Hi-Lite™ comprises liquid (35% hydrogen peroxide) and powder (base material, catalyst, color indicator, etc.). Power Gel™ comprises only powder that includes similar ingredients to those of Hi-Lite™, and it is used by mixing the powder and 35% hydrogen peroxide. In both cases, an ARC Light™ II (approximately 1,000 mW/cm<sup>2</sup>) was used as the visible light source for effective activation of hydrogen peroxide.

A rubber dam dry field technique is important to prevent injury of oral soft tissue by leakage and swallowing of the active agent. However, use of the rubber dam can be uncomfortable for the patient. Recently, light-cured gum protective materials have become available. Gun Dam™ is one such product that is simple to use in the office, but it should be used carefully to avoid dropping the agent into the oral cavity and accidental swallowing.

The color difference ( $\Delta E$ ) resultant upon the bleaching process was quantified according to the color difference table of Ibusuki<sup>19)</sup>. In Case-1, the tooth shade changed from C-3, -4 to C-1, -2 as a result of treatment. The color difference ( $\Delta E$ ) was 6.4-6.5. In Case-2, the tooth shade changed from B-3 to A-2, and  $\Delta E$  was 5.8. Ibusuki reported that  $\Delta E$  of 3.0-6.0 implies a considerable color change, and  $\Delta E$  6.0-12.0 implies an extreme color change<sup>19)</sup>. Yamaguchi et al.<sup>3)</sup> reported that in-office bleaching of tetracycline-induced tooth discoloration using Hi-Lite™ resulted in  $\Delta E$   $6.36 \pm 2.98$ . In the present reports, treatment resulted in a considerable or extreme color change, and our results are consistent with those of Yamaguchi et al. In Case-2, only two applications of the tooth bleaching material were required to cause a  $\Delta E$  of 5.8.

### Conclusion

In-office bleaching of tetracycline-discolored and yellow teeth was performed using Hi-Lite™ and Power Gel™, respectively. Our results demonstrated excellent improvement in

tooth color in both cases, with a color difference ( $\Delta E$ ) of 5.8-6.5 from pre- to post-treatment. In-office bleaching is a safe and reliable method for the treatment of tooth discoloration. We are currently gathering data on the results of at-home bleaching.

### Acknowledgments

These data were reported in part at the 13<sup>th</sup> Meeting of the Japan Academy of Esthetic Dentistry (November 17, 2002, Tokyo).

### References

1. Kawahara D and Shirai S : Marketing. Kawahara D and Shirai S. (Eds.), Recent Status of Tooth Whitening., Ishiyaku Publishers Inc., Tokyo, 7-14, 2002.
2. Saito T, Ibaraki Y, Shirai S, et al : Clinical results for vital tooth bleaching: predicting effects of bleaching based on color difference. *J Esthet Dent*, in press, 2003.
3. Yamaguchi R, Shinkai K, Kato Y, et al : Clinical Performance of Bleaching with SHOFU Hi-Lite™. *Jpn J Conserv Dent*, **40**, 204-233, 1997.
4. Kawai O, Ibaraki Y, Nakashima K, et al : Color recovery of discolored anterior teeth by bleaching with Hi Lite®. *Jpn J Conserv Dent*, **42**, 695-702, 2000.
5. Toko T, Yaoita E, Saito Y, et al : Clinical Results of the Bleaching Method for Discolored Vital Teeth by Using Nite White Excel™. *Jpn J Conserv Dent*, **41**, 985-1008, 1998.
6. Haywood VB and Heymann HO : Nightguard vital bleaching. *Quintessence Int*, **20**, 173-176, 1989.
7. Haywood VB, Leonard RH, Nelson CF, et al : Effectiveness, side effects, and long-term status of nightguard vital bleaching. *J Am Dent Assoc*, **125**, 1219-1226, 1994.
8. Haywood VB : History, safety, and effectiveness of current bleaching techniques and applications of nightguard vital bleaching technique. *Quintessence Int*, **23**, 471-488, 1992.
9. Swift EJ, May KN, Wilder AD, et al : Two-year clinical evaluation of tooth whitening using an at-home bleaching system. *J Esthet Dent*, **11**, 36-42, 1999.
10. Leonard RH, Haywood VB, Eagle JC, et al : Nightguard vital bleaching of tetracycline-teeth : 54 month post treatment. *J Esthet Dent*, **11**, 265-277, 1999.
11. Matil BA : The efficacy and safety of a 10% carbamide peroxide bleaching gel. *Quintessence Int*, **29**, 555-563, 1998.
12. Goldstein DE : Bleaching vital teeth : State of the art. *Quintessence Int*, **20**, 729-737, 1989.
13. Arens DE, Rich JJ, Healey HJ : A practical method of bleaching tetracycline-stained teeth. *Oral Surg Oral Med Oral Pathol*, **34**, 812-817, 1972.
14. Christensen GJ : Bleaching vital tetracycline stained teeth. *Quintessence Int*, **9**, 13-19, 1978.
15. Putter H and Jordan RE : The "walking" bleach technique. *J Esthet Dent*, **1**, 191-193, 1989.
16. Casey LJ, Schindler WG, Murata SM, et al : The use of dentinal etching with endodontic bleaching procedures. *J Endod*, **15**, 535-538, 1989.
17. Liebenberg WH : Intracoronal lightening of discolored pulpless teeth : a modified walking bleach technique. *Quintessence Int*, **28**, 771-777, 1997.
18. Hisamitsu H and Toko T : Whitening of discolored teeth. Onose H, Inoue H, Hirai Y, Tanaka H. (Eds), Restorative Dentistry, Ishiyaku Publishers Inc., Tokyo, 305-314, 2000.
19. Ibusuki M : Art of tooth crown color. GC, Tokyo, 13-14, 1992.