

[CLINICAL REPORTS]

Idiopathic Bone Cavity of the Mandible

Masayuki KANEKO, Yoichiro HOSOKAWA, Takashi OHNISHI
Tomoaki SANO and Megumi FUKUDA

Department of Dental Radiology, School of Dentistry
Health Sciences University of Hokkaido

(Chief : Prof. Masayuki KANEKO)

Abstract

A case of an idiopathic bone cavity is presented and discussed. The patient was a 54-year-old Japanese male with a history of stomach carcinoma operation and hospitalization two years ago. He was referred to the Department of Dental Radiology with a panoramic radiograph performed by the dentist. The panoramic radiograph demonstrated a well-defined elliptical radiolucent lesion near the right angle of the mandible, situated below the mandibular canal and slightly above the inferior border of the mandible. The patient stated that the lesion progressed asymptotically without any sensation. From the lesion was indicated, the patient was greatly anxious about metastasis of stomach carcinoma to the mandible. To define the diagnosis of the lesion, intraoral radiography, extraoral radiography, tomography, and sialography were carried out. All results showed that the lesion was an idiopathic bone cavity without relationship to salivary gland tissue. No biopsy was carried out, but the lesion was diagnosed to be benign, and a metastatic carcinoma was ruled out.

Key words : Idiopathic bone cavity, Stafne's bone cavity, Developmental bone defect

Introduction

Idiopathic bone cavity is a relatively rare anomaly with an incidence of about 4 in every 1000 adults¹⁾. More cases have been reported in men than in women.

This cavity was first described by Stafne²⁾ in 1942, who reported 34 cases of radiolucent abnormalities observed near the mandibular angle. These cavities were all detected by intraoral radiography. They appeared below the submandibular canal and slightly above the inferior border of the mandible as ovoid or round radiolucencies. The idiopathic bone cavity has other

Accepted : March 22, 1995

names such as the "developmental bone defect³), static bone cavity^{1,4}), latent bone cyst⁵), aberrant salivary gland defect⁶), lingual mandibular bone cavity⁷), and Stafne's bone cavity⁸)." The contents of the idiopathic bone cavity have been studied radiographically, histopathologically, and surgically. Most of the tissue contained in the cavity is salivary gland tissue^{6,9-15}), followed by fatty tissue, lymphatic tissue, and other connective tissue¹⁵⁻¹⁷).

The idiopathic bone cavity develops asymptotically and is next to impossible to palpate manually, and it is only discovered during radiographic examinations. The most common radiographic images are round, ovoid, or elliptical radiolucencies that vary from 1 to 3 cm in diameter. It is generally found below the mandibular canal and above the inferior border of the mandible^{2,18}). The appearance and location of the radiographic image of the idiopathic bone cavity are very characteristic that the lesion is readily recognized. However, a differential diagnosis may be necessary when the lesion is situated more anteriorly or more superiorly to its usual location or when in a dentulous area. The lesion need not require surgical exploration, except in cases where malignant salivary gland neoplasm is suspected in the soft tissue within the cavity. Consequently, the images should be examined carefully and the areas must be adequately palpated. Repeating the examination after about 3 to 6 months is necessary to confirm that a defect is not growing. The present report is of a case of idiopathic bone cavity which appeared in a 54-year-old Japanese man with a past history of stomach carcinoma operated and hospitalized 2 years previously.

Case Report

The patient was referred to the Department of Dental Radiology with a panoramic radiograph performed by the regular dentist. The panoramic radiograph showed an extremely well-defined ovoid or elliptical radiolucent lesion in the patient's right mandible. The lesion was observed below the mandibular canal and above the inferior border of the mandible, as shown in Fig. 1. No past history except the stomach carcinoma operation and hospitalization 2 years previously were established. There were no noteworthy events in the family history either. The patient stated that the lesion had progressed asymptotically without sensation, and there was great anxiety about metastasis of a stomach carcinoma to the mandible.

Deformities or swellings of the maxillofacial regions were not seen by optical examination and manual palpations, as shown in Fig. 2-a.

Intraoral examinations indicated no expansion of the mandible, as shown in Fig. 2-b. The results of hematologic and biochemical investigations were within the normal range. No biopsy of the lesion was performed to avoid surgical damage. All findings obtained at the first admission suggested that the lesion could be an idiopathic bone cavity caused by the existence of aberrant salivary gland tissue which had gradually developed into the cavity.

To determine this, intraoral and extraoral radiography, tomography, and sialography were carried out.

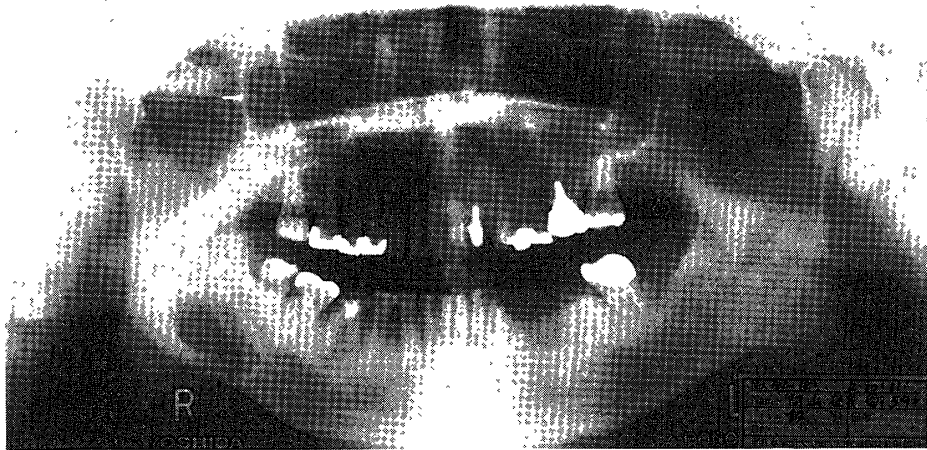


Fig. 1. Panoramic radiograph performed by the patient's dentist, showing a well-defined radiolucent lesion near the right angle of the mandible.

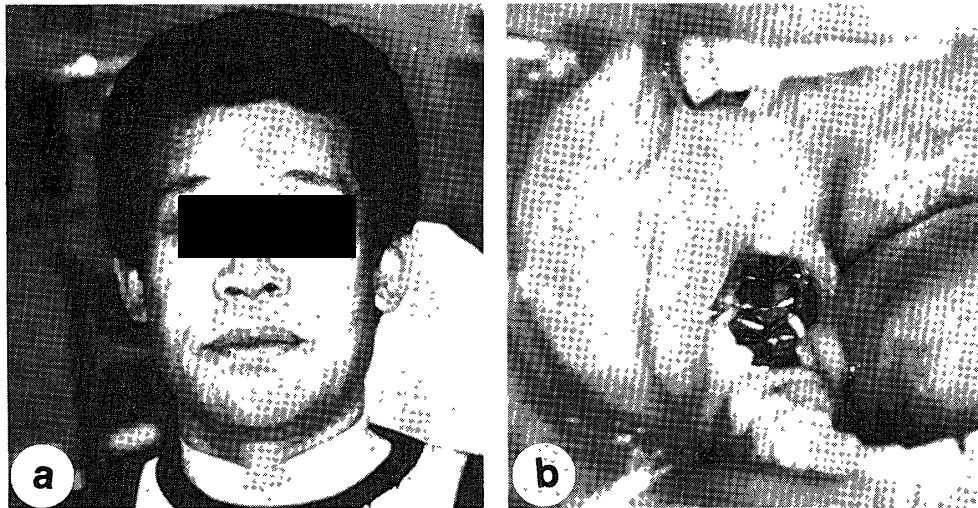


Fig. 2. Facial (a) and intraoral (b) appearance of the patient, showing neither deformities nor swellings.

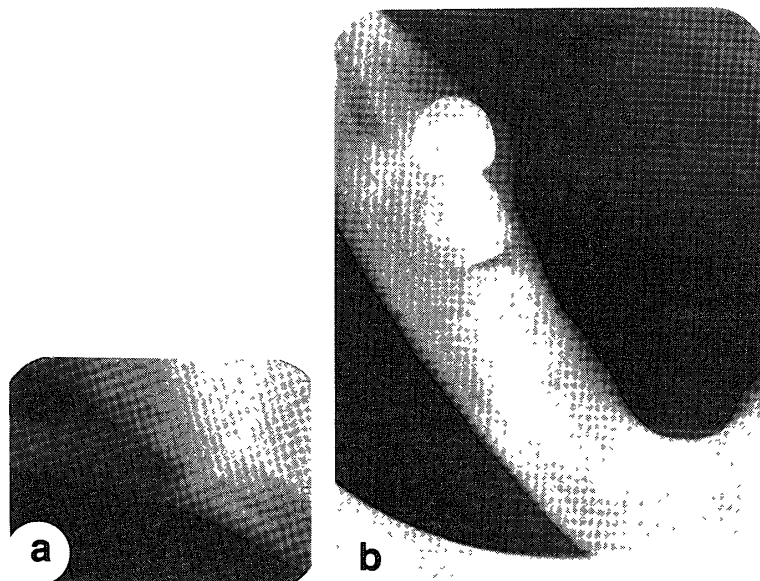


Fig. 3. Periapical (a) and axial (b) radiographs obtained at the first admission.

A periapical radiograph obtained with tangential projection (Fig. 3-a) showed a well-defined ovoid radiolucency below the mandibular canal and slightly above the inferior border of the mandible. The rarified area is circumscribed by a dense radiopaque line that continued from the inferior cortex of the mandible. The inferior border of the cavity appeared absent, typical for an intraoral radiographic image of an idiopathic bone cavity.

The axial projection image demonstrated a comparatively well-defined elliptical radiolucency in the retromolar region of the mandible, with a comparatively thick and clear wall extending toward the buccal direction from the lingual side of the mandible (Fig. 3-b).

The posteroanterior and lateral plane images showed an ovoid radiolucent lesion in the right angle of the mandible, situated below the man-

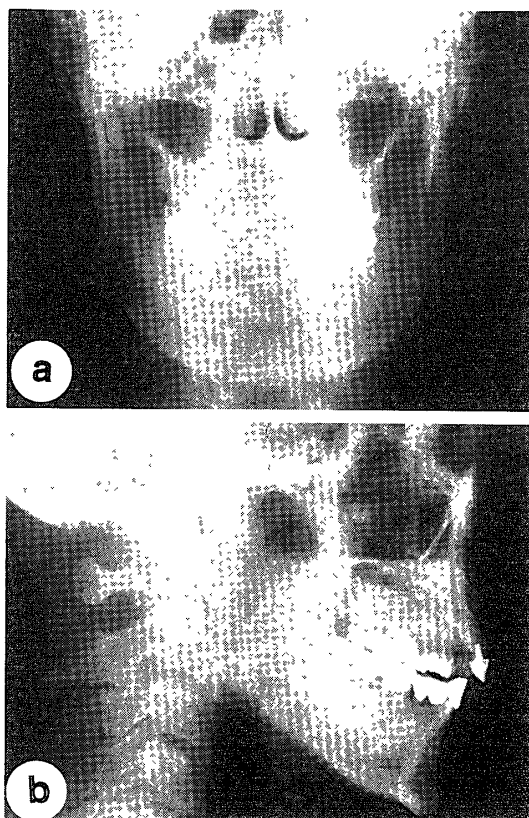


Fig. 4. Posteroanterior (a) and lateral (b) radiographs obtained at the first admission.

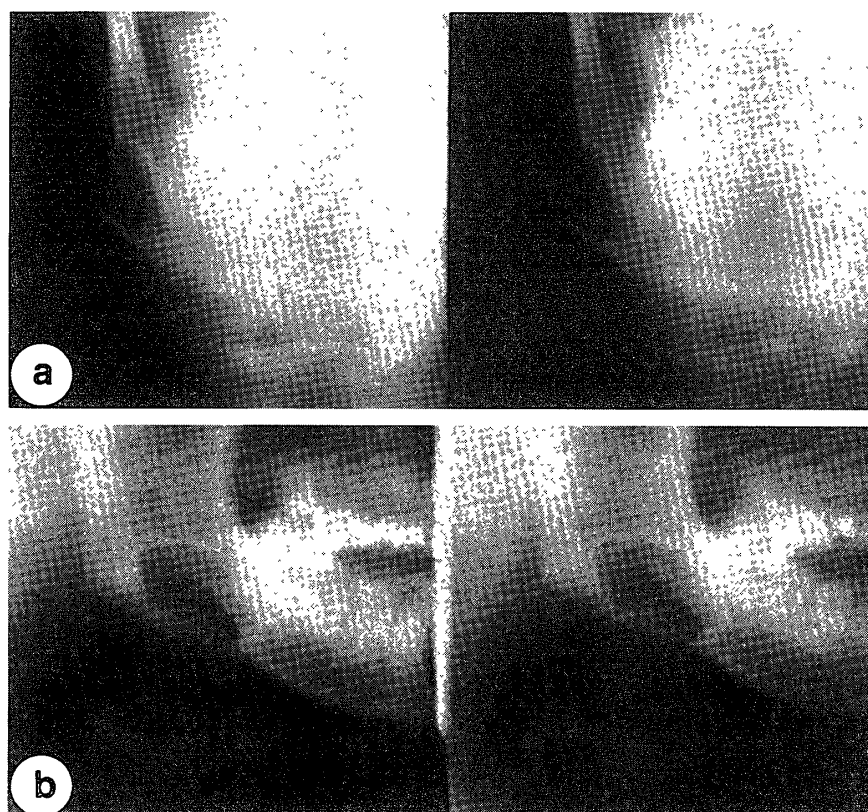


Fig. 5. Posteroanterior (a) and lateral (b) tomographs to examine the depth of the concavity.

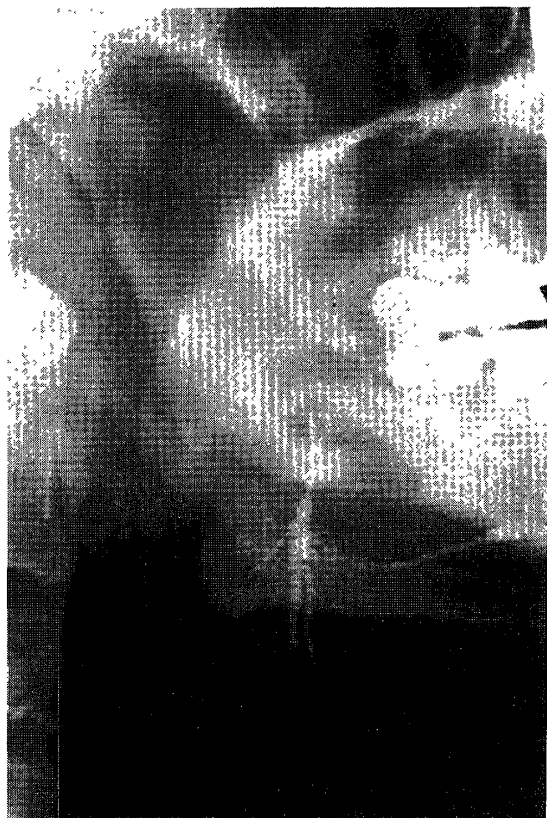

Fig. 6. Sialogram examining the relationship between the cavity and salivary gland tissue.

dibular canal and above the inferior border of the mandible (Fig. 4).

The tomographic images (Fig. 5) showed that the lesion was a concavity extending from the lingual surface of the mandible toward the buccal direction.

The sialogram (Fig. 6) obtained to examine if the cavity was related to aberrant salivary gland tissue demonstrated a normal salivary gland image. So that there was no relationship between the cavity and the salivary gland tissue. The contents of the cavity were not determined by biopsy, but other tissue may have caused the idiopathic bone cavity.

In the present case, differential diagnoses had to be carried out as the patient was anxious about metastatic carcinomas to the mandible.

In general, metastatic carcinomas demonstrate osteolytic lesions with an ill-defined moth-eaten appearance. Well-defined radiopaque lines are seldom observed. Prostatic adenocarcinoma also readily metastasize to bone. But this is usually osteoblastic and, therefore, radiopaque. No findings from the present case showed both of these appearances which would suggest malignant tumors metastasized to the mandible, and the lesion was diagnosed to be benign.

The final diagnosis was performed radiographically and showed that the lesion was an idiopathic bone cavity caused by substances such as fatty tissue or other connective tissue in the cavity.

Discussion

Idiopathic bone cavities have been comparatively well documented since Stafne first described 34 cases of this lesion in 1942²⁾. This anomaly has been documented to occur in approximately 1 of 250 panoramic radiographs^{1,19)}. As indicated by the age at onset, and by documentation of the development of the defect, it seems reasonable to assume that this condition is developmental rather than congenital^{2,3,20,21)}.

The defect usually appears as a well-defined, ovoid, unilocular radiolucency with an opaque border, located below the mandibular canal and slightly above the inferior border of the mandible. Cortical bone sometimes seems to be absent. Anterior lingual defects were also reported by some authors^{17,22)}.

The etiology of the idiopathic bone cavity has been examined radiographically, surgically, and histopathologically. Most of the defects investigated by biopsy contained salivary gland tissue^{6,9-15}). The tissue is reported to cause focal pressure resorption of the lingual cortical plate of the mandible with consequent thinning of the lingual plate to the point where it may be seen radiographically. Other salivary gland tissue reported is fat tissues and, other connective tissue^{15,17}).

Idiopathic bone cavities almost always grow asymptotically and are first detected accidentally in routine radiographic examinations^{2,18}). The cortical bone sometimes appears to be absent so the defect is not a closed bone cavity. In the present case, too, the intraoral radiographic image showed an elliptical radiolucency on the corner of the radiograph, in which the cortical bone seemed absent, like those obtained by Stafne²). The radiographic appearance, location, clinical findings of asymptomatic development, and intraoral absence of expansion of bone suggested a great possibility that the lesion could be an idiopathic bone cavity. To confirm the differential diagnosis effectively, more extraoral and panoramic radiography was necessary and posteroanterior and lateral projections, tomography and sialography were added. The posteroanterior and lateral plane images also showed a well-defined radiolucent lesion adjacent to the buccal cortex of the right mandible. The mandibular canal was observed not to be related with the radiolucent area. Tomographic images also showed that the lesion extended toward the buccal surface of the mandible. The buccal cortex of the mandible was well defined. The radiographic images showed that the concavity was open toward the lingual direction, and that the buccal region was closed by the cortex. Such an appearance is seldom seen in carcinomas that are metastasized to the mandible²³), excluding the possibility of a metastatic carcinoma.

To evaluate the relationships between the idiopathic bone cavity and salivary gland tissue, sialography seems effective if the lesion is related to salivary gland tissues which press to the surface of the mandible^{8,18,21,24}). In the present case, however, the sialogram showed a normal salivary gland image. This showed that the cavity has no relationship with the salivary gland tissue, and although no biopsy was carried out, it suggested that the concavity was caused by other tissue such as fat. Further detailed investigation is necessary to confirm the etiology of idiopathic bone cavities.

References

1. Karmiol M, Walsh R. Incidence of static bone defect of the mandible. *Oral Surg Oral Med Oral Pathol* 1968 ; 26 : 225-8.
2. Stafne EC. Bone cavities situated near the angle of the mandible. *J Am Dent Assoc* 1942 , 29 . 1969-72
3. Tolman DE, Stafne EC. Developmental bone defects of the mandible. *Oral Surg Oral Med Oral Pathol* 1967 ; 24 : 488-90.
4. Bernstein HF, Lam RC, Pomiji FW. Static bone cavities of the mandible: review of literature and report of a case. *J Oral Surg* 1958 ; 16 : 46-52.
5. Thoma KH. Case report of a so-called latent

- bone cyst. *Oral Surg Oral Med Oral Pathol* 1955 ; 8 : 963-6.
6. Amaral WJ, Jacobs DS. Aberrant salivary gland defect in the mandible: report of a case. *Oral Surg Oral Med Oral Pathol* 1961 ; 14 : 748-52.
 7. Olech E, Arora BK. Lingual mandibular bone cavity. *Oral Surg Oral Med Oral Pathol* 1961 ; 14 : 1360-6.
 8. Ariji E, Fujiwara N, Tabata O, Nakayama E et al. Stafne's bone cavity: classification based on outline and content determined by computed tomography. *Oral Surg Oral Med Oral Pathol* 1993 ; 76 : 375-80.
 9. Boerger WG, Waite DE, Carrol GW. Idiopathic bone cavities of the mandible; a review of the literature and report of a case. *J Oral Surg* 1972 ; 30 : 506-9.
 10. Choukas NC, Toto PD. Etiology of static bone defect of the mandible. *J Oral Surg* 1960 ; 18 : 16-20.
 11. Mark LM, Woodward HW. Static bony defect of the mandible. *J Oral Surg* 1969 ; 27 : 262-5.
 12. Choukas NC. Developmental submandibular gland defect of the mandible: review of literature and report of two cases. *J Oral Surg* 1973 ; 31 : 209-11.
 13. Jacobs MH. The traumatic bone cyst. *Oral Surg Oral Med Oral Pathol* 1955 , 8 : 940-9.
 14. Fordyce GL. The probable nature of so-called latent haemorrhagic cyst of the mandible. *Br Dent J* 1956 ; 101 : 40-2.
 15. Hayashi Y, Kimura Y, Nagumo M. Anterior lingual bone concavity. *Oral Surg Oral Med Oral Pathol* 1984 ; 57 : 64-8.
 16. Bergenholtz A, Persson G. Idiopathic bone cavities: report of four cases. *Oral Surg Oral Med Oral Pathol* 1969 ; 16 : 703-12.
 17. Buchner A, Carpenter WH, Merrell PW, Leider AS. Anterior lingual mandibular salivary gland defect: evaluation of twenty-four cases. *Oral Surg Oral Med Oral Pathol* 1991 ; 71 : 131-6.
 18. Stafne EC. Anomalies. In: Gibilisco JA, eds. *Stafne's Oral radiographic diagnosis*, 5th edition. Philadelphia, London, Toronto, Mexico City, Rio De Janeiro, Sydney, Tokyo, Hong Kong: W.B. Saunders, 1985 : 18-45.
 19. Johnson CC. Analysis of panoramic survey. *J Am Dent Assoc* 1970 ; 81 : 151-4.
 20. Hansson L. Development of a lingual mandibular bone cavity in an 11-year-old boy. *Oral Surg Oral Med Oral Pathol* 1980 ; 49 : 376-8.
 21. Seward GR. Salivary gland inclusions in the mandible. *Br Dent J* 1960 ; 108 : 321-5.
 22. Connor MS. Anterior lingual mandibular bone cavity: report of a case. *Oral Surg Oral Med Oral Pathol* 1979 ; 48 : 413-4.
 23. D'Eramo EM, Poidmore SJ. Developmental submandibular gland defect of the mandible: review of the literature and report of a case. *Oral Surg Oral Med Oral Pathol* 1975 ; 39 : 14-9.
 24. Uemura S, Fujishita M, Fuchihata H. Radiographic interpretation of developmental defects of the mandible. *Oral Surg Oral Med Oral Pathol* 1976 ; 41 : 121-6.