

[CLINICAL report]

Application of low-frequency electricity and stellate ganglion block therapy to inferior alveolar neuroparalysis following tooth extraction –Evaluation of facial skin temperature elevations via thermography–

Takuro KAWAI¹⁾, Masaru KUDO¹⁾, Tomochika YANAGI^{2),3),4)} and Noboru SHINYA¹⁾

¹⁾Department of Dental Anesthesiology, School of Dentistry,
Health Sciences University of Hokkaido

²⁾Department of Dental Materials Science

³⁾Second Department of Oral Maxillofacial Surgery

⁴⁾Takikawa Dental Clinic

Abstract

Mentolabial paralysis occurs as a result of inferior alveolar nerve injury consequent to tooth extraction. Stellate ganglion block (SGB) therapy, acupuncture and magnetic electrotherapy (AME) are utilized for the treatment of neuroparalysis following tooth extraction. The SGB therapy includes 30 injections (2–3 times/week) as a single set, and subsequently, the therapeutic effects are re-evaluated. To determine the efficacy of the treatment, patient symptoms and skin temperature increase at the site of the hypoesthesia serves as indices.

Subtle temperature changes, which were detected via thermography, were converted into numeric values in this study. Treatment was conducted in collaboration with the family dentist over a 20-month period from the 5th to the 25th month from the onset of the hypoesthesia. The mean temperatures at the site of the hypoesthesia was compared, for an SGB-only (n=5) and an SGB/AME combination (n=5) treatment.

The results found that the level of hypoesthesia, which was measured with a Semmes–Weinstein monofilament (SW) sensory tester, improved from $\phi 3.84$ to $\phi 2.44$ – 3.22 . The temperature at the site of the hypoesthesia increased by 0.8°C following the SGB injection; in contrast, the temperature at the site of hypoesthesia increased by 2.5°C following application of the SGB/AME combination. In inferior alveolar neuroparalysis arising as a consequence of tooth extraction, the surface thermographic temperature measurement at the site of the hypoesthesia was effective to observe the temperature increase due to SGB injection and to the SGB/AME combination; additionally, it offers a substantiation for the treatment efficacy for the patients.

Key words : Stellate ganglion block, Acupuncture and magnetic electrotherapy, Thermography, Inferior alveolar neuroparalysis, Medical lawsuit

Introduction

Stellate ganglion block (SGB) therapy, acupuncture, and magnetic electrotherapy (AME) are utilized in the treatment of neuroparalysis following tooth extraction. The SGB therapy comprises of a set of 30 injections (2–3 times/week); subsequently, the therapeutic effects are re-evaluated.

To assess the suitability of injections, subjective symptoms of each patient as well as the skin temperature elevation at the site of the paralysis were evaluated. The skin temperature elevation was examined via thermography (THG) following implementation of AME and SGB in a case characterized by paralysis. Originally, the individual had been subjected to continuous dental laser irradiation.

受付 : 平成17年 3 月31日

Methods

1. Therapeutic Methods

1) SGB (Stellate Ganglion Block)

The SGB, which offers temporary pain relief in terms of sympathetic tone, is achieved via the injection of local anesthetic in the cervical sympathetic ganglion area. Consequently, the blood flow (Kakuyama et al., 2000) and metabolism at the site are stimulated as a result of vascular dilation; thus, the body temperature is elevated on the side of the cervical sympathetic ganglion injection (Matsumoto et al., 1992). The SGB is applied to various disorders, including allergic rhinitis, sudden deafness, autonomic nerve imbalance, angina and lower limb pain. In the dental field, SGB is employed in instances of post-extraction pain and paralysis, tongue pain and peripheral facial paralysis. The treatment at the hospital here uses lidocaine hydrochloride (6ml, 2% solution) or a mixture of lidocaine hydrochloride (4ml, 2%) and bupivacaine hydrochloride (2ml, 0.25%, total 6ml, solution) as local anesthetics for the SGB injections.

Injection is conducted from the front side with the patient in the dorsal position. The cervical transverse process serves as an indicator point (Fig. 1).

Body temperature elevation at the block side, blepharoptosis, pupil constriction and palpebral conjunctiva hyperemia are evaluated to assess the sympathetic tone relief. Most patients experience a "warm sensation" and sleep for 30–60 minutes following the injection. The injection diagram depicted in Figure 1, which offers an explanation for the SGB procedure, is shown to the patient.

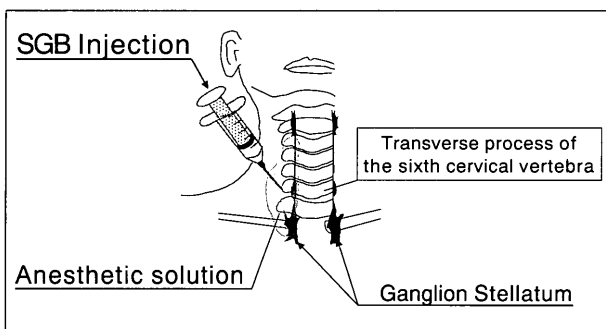


Fig. 1 Front penetration image SGB injection
An expanse of anesthetic solution Injection of Stellate ganglion block(SGB).

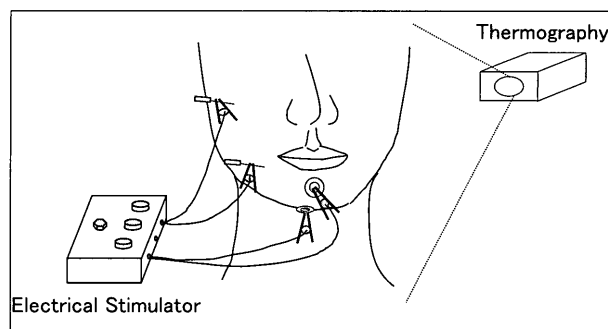


Fig. 2 The method of electrical stimulation
Magnet or acupuncture was used for the treatment of electrical stimulation.
Stimulation conduction : 2Hz, bipolar pulse wave. Intensity of stimulation : either muscle contraction(+)and pain(-).
The effect of electrical stimulation was assessed by the increase of surface temperature.
Surface temperatures of patient's face were measured by thermography.

2) AME

In AME, magnetic electrode attachment or acupuncture needle insertion is completed at various pressure points(3points on the face, between the bases of the thumbs and index fingers, the inner side of the elbow and underneath the chin); subsequently, a 2-Hz electric current is applied (Fig. 2). The AME is reported to promote blood flow and to elevate skin temperature via a stimulation of polymodal receptors with low-frequency electricity and magnetic force (Takeshige and Sato, 1996). The objective of this particular treatment is restoration of patient sensory function. Reduction of the nerve paralysis level and minimization of the paralysis area were examined. In addition, appropriate sympathetic tone relief was estimated by monitoring the skin surface temperature and temperature increases in the mucous membranes and the tongue of the mouse employing the THG apparatus (TH5104R, NEC) or an infrared eardrum thermometer (Genius™, Tyco Healthcare).

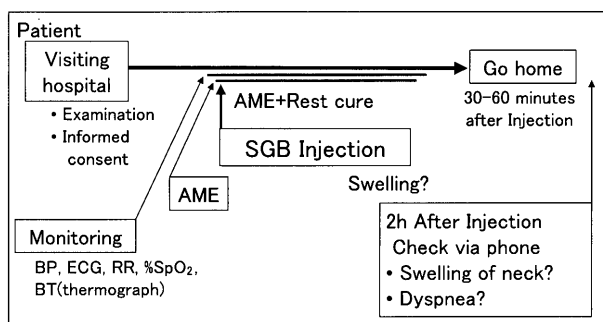


Fig. 3 Therapeutic flow of SGB injection in dental anesthesia
SGB injection was administered 30 minutes following the initiation of AME. The patient rested for 30–60 minutes following application of SGB. The patient was monitored continuously during the resting phase for early detection of any incidental symptoms.. SGB : stellate ganglion block AME : Acupuncture magnetism of electrical therapy

3) Therapeutic process

Monitoring was initiated with the patient lying down in a face-up position, and SGB injection was administered 30 minutes after the initiation of AME. The sites for needle insertion were compressed for 5 minutes to establish the absence of dizziness, light-headedness, swelling or bleeding. The patient rested for 30–60 minutes application of SGB therapy. The patient was monitored continuously during the resting phase to ensure a speedy detection of incidental symptoms. The patient was released after confirming the absence of abnormal vital signs, hematoma, respiratory difficulties, dizziness, or light-headedness (Fig. 3). Table 1 shows a therapeutic plan of SGB and AME from the initial screening till the goal of the treatment, which adheres to the Japan Society of Pain Clinicians treatment guidelines (Table 1). A Semmes-Weinstein monofilament (SW) sensory tester, was utilized for the initial diagnosis and re-evaluation. The SW sensory tester quantitatively evaluated patient sensory functions with silicon filaments of various thicknesses. The thinner filament indicated stronger paralysis.

Case Report

1. Patient condition and medical history

Following an explanation of the risks involved, the individual underwent lower left wisdom tooth extraction at the age of 38 years. The patient received a local anesthetic (2% lidocaine hydrochloride with 1 : 80,000 epinephrine) injection with sedative, and the vital signs were monitored. The patient repeatedly complained of pain despite the delivery of 12.2 ml of anesthetic during the 145-minute procedure. Antibiotics and a sedative were prescribed after the operation. The day immediately after the tooth extraction, the individual complained of occlusion discomfort as well as numbness in the chin. Partial neuromesis of the inferior alveolar nerve was suspected. Vitamin B12, multivitamins and ATP medication were administered. Low-level laser irradiation (1–2 times/week) was also administered for five months; however, this was ineffective.

2. Diagnosis and treatment in the dental anesthetic department.

At 5 months after the tooth removal, the patient was admitted to dental anesthetic department at HSUH dental hospital. Sensory tester diagnosis indicated a paralysis of 48 mm × 40 mm, > ϕ 3.84 in the right mental nerve area. The individual also complained of other discomfort such as abnormal heat sensitivity (hot drinks felt excessively hot). A diagnosis of the paralysis by drug-induced temporary conduction disturbance was administered. The individual was advised about and asked to choose SGB and/or AME treatment (needle electricity : insertion of Japanese acupuncture needles in facial and frontal arm pressure points for conduction of an electric current).

The patient chose AME, and evening treatments were planned (once per week). Additionally, CO₂ laser irradiation was used to improve the effectiveness of the therapy. No improvement was seen after five months of AME treatment (total 10 treatments, now 10 months after the tooth extraction). Consequently, SGB therapy was initiated. Further, after a 9-month AME regime (20 treatments, till 14 months after the tooth extraction), a combination of the SGB injections and AME therapy was performed.

Days after onset	-14 days	15 - 89 days	90 - days
Examination	• Sensory test • Facial skin temperature • Dental pulp blood flow	• Sensory test • Facial skin temperature • Dental pulp blood flow	• Sensory test • Facial skin temperature • Dental pulp blood flow
Treatment	• SGB injection 2 - 5 / week 30 times	• SGB injection 2 / week 30 times	• SGB injection 1 - 3 / week • AME
Drug	• Vit B ₁₂ : 1.5g • ATP :180mg 3x/14days	• Vit B ₁₂ : 1.5g • ATP :180mg 3x/14days	• Vit B ₁₂ : 1.5g 3x/14days
Prognosis	• good	• moderate	• severe

Table 1 The guideline for trigeminal nerve injury in dental anesthesiology at HSUH dental hospital

If patients start to receive our treatment as soon as they can, their prognoses will get better.

HSUH : Health sciences university of Hokkaido SGB : stellate ganglion block AME : Acupuncture magnetism of electrical therapy.

To evaluate the efficacy of the SGB injections as well as the combination SGB injection/AME therapy, the skin surface temperature was non-invasively and continuously monitored via thermography. The SGB injection efficacy is illustrated in Figures 4 and 5. Average skin temperature of the paralysis site and the lower eye socket served as indicators.

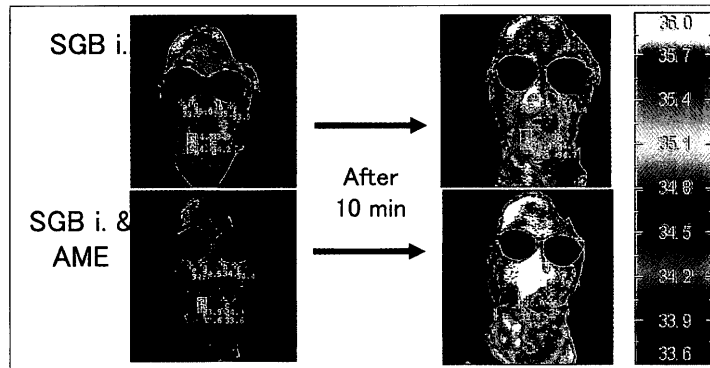


Fig. 4 Effect of increase BT by SGB injection and AME
 The changing of patient' facial skin temperature by thermography in a case of Disturbance of inferior alveolar nerves. Room temperature was 26–28°C. SGB i : stellate ganglion block injection

3) Therapeutic medical effects

In Fig. 4, the upper left corner indicates the conditions prior to the block, while the upper right corner indicates the conditions 10 minutes after the SGB injection. The temperature increase was 0.9°C (34.4–35.3°C) on the injection side and 0.7°C on the normal side (Fig. 4). The combined therapy involving SGB and AME demonstrated higher temperature elevations in the head and neck area than with the application of SGB alone. The area of hypoesthesia had a 0.8°C increase with SGB, and using AME the increase was 2.5°C (Fig. 5).

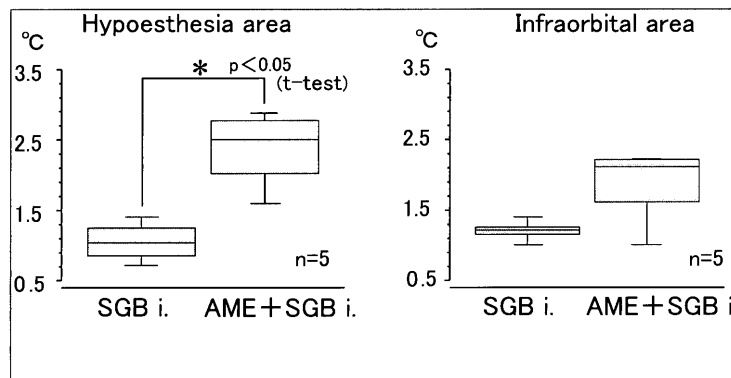


Fig. 5 Difference of hypoesthesia area and infraorbital area BT
 Increase of temperature on surface of facial skin, after 10 minutes from the end of SGB injection Dates of SGB injection are shown as the average of five times increases of temperature on surface of facial skin for one patient. Facial temperatures were increased 0.8°C at hypoesthesia area by SGB injection, and 2.5°C at hypoesthesia area by AME+SGB. The increase of AME+SGB was significantly higher than that of SGB. SGB i : stellate ganglion block injection

The individual did not complete the treatment (Final treatment 32 courses of SGB injection, at 20 months from initiation of therapy, 26 months from the tooth extraction). At the last treatment the area of hypoesthesia was unchanged (38mm X40 mm), the paralysis level had improved to ϕ 2.44–3.22, occlusion discomfort had improved (from + to \pm), and the abnormal heat sensitivity had decreased. The patient was informed of the low probability of a complete cure with continued therapy and the treatment was discontinued. The patient continued the laser irradiation treatment at a family practice clinic.

Discussion

The pain clinic at the hospital treats patients with inferior alveolar paralysis, facial paralysis, glossalgia, masticatory muscle myofascial syndrome, and temporomandibular disorders, conditions that are not caused by brain nerve or blood vessel dysfunction. In the current case, the numbness and paralysis in the lower lip resulted from a partial rupture of the inferior alveolar nerve due to extraction of a lower jaw wisdom tooth. Paralysis in this instance is iatrogenic in nature. Consequent to the ap-

pearance of this disorder, many patients refuse SGB or needle-type treatments, and patient refusal results in a delayed start of SGB treatment. The initiation of SGB treatment as rapidly as possible is essential in cases involving neural paralysis (Imamura et al., 2000), but an early implementation of the SGB treatment, and thus prevention of further induction of incidental symptoms, requires resolution of patient fears regarding needle-type regimes involving the neck and head regions. At the hospital dental anesthetic department (pain clinic), patients are carefully monitored to facilitate delivery of immediate medical attention in the event of complications arising from anterior neck region needle insertion. The patient reported here had 32 needle insertions with no serious side effects. Currently, magnetic electricity is employed for induction of SGB, and the introduction of SGB under nitrogen monoxide and oxygen inhalation / sedation with careful vital sign monitoring and near-infrared exposure is presently under review with respect to patient anxiety (Kudo, 2003).

Many patients are referred by other in-hospital departments or by dental professionals in nearby cities, for patient convenience, the pain clinic is open in the evenings twice a week. Close communication with the patients' family dentists and doctors is essential. In general, office hours of general hospitals and university medical centers are more limited, and to assess patient needs there are plans to expand pain clinic hours to two nights per week.

Following the combination of SGB and AME therapy and SGB application alone, facial skin temperature was elevated at the site of the paralysis. The combined therapy allowed the detection of the elevation in facial skin temperature at the site of the paralysis with improvement in paralysis levels (temporary conduction disturbance); however, paralysis was not completely cured.

The main factor influencing this outcome was the delayed SGB and AME application following the development of the paralysis; further, patient age (38 years) and a busy work schedule contributed to the therapeutic delay. Treatment was ultimately discontinued, but a medical malpractice suit was avoided due to patient understanding.

Many instances of inferior alveolar neuroparalysis can be attributed to nerve damage in the mandible as a result of tooth removal. Therefore, an assessment of treatment efficacy requires careful observation of blood flow increases in the mandible and the mandibular canal in addition to thermography. Our department is also capable of blood flow measurements in the peripheral dental pulp, and future combinations of such methodologies with conventional therapies is desirable in order to accommodate long-term inferior alveolar neuroparalysis. There are several reports of successful steroid therapy in similar cases (Seo et al., 2004). To improve sensory function, immediate hospital admission at the time of symptom development, administration of short-term concentrated therapy, application of laser irradiation and near-infrared exposure, all in combination with steroid therapy appear desirable. Many dentists will require instruction in their novel therapeutic strategies.

Conclusion

Measurement of the skin surface temperature via thermography were effective in the diagnosis and prognosis predictions in cases of inferior alveolar neuroparalysis following tooth removal. Five months after the development of paralysis, SGB and/or AME therapy was conducted for 20 months with the cooperation of the family dentist; subsequently, paralysis symptoms improved. An early start of SGB therapy is desirable to promote iatrogenic peripheral nerve damage treatment and to avoid intractability.

References

Imamura. Y, Sakamoto Y, Shiiba E, Iwamoto M, Kawahara H, Yasusaka M, Tahara F, Nakashima A, Fukuda J and Nakanishi O. Predicting the prognosis of abnormal sensation after dental treatment –Using self reported symptoms–. *J Jpn Dent Soc Anesthesiol* 28 : 27–35, 2000.

Kakuyama M Toda H, Osawa M and Fukuda K. The bilateral effect of stellate ganglion block on the facial skin blood flow. *Reg Anesth*

Pain Med 25 : 389–392, 2000.

Kudo M. Efficacy of nitrous oxide/oxygen inhalation sedation in dentistry –providing painless, and comfortable dental treatment. *Medical Gases* 5 : 47–53, 2003.

Matsumoto S, Mitsuhata H and Hasegawa J. Thermographic assessments of the sympathetic blockade after stellate ganglion block (no.3) –the block at the base of the 6th cervical transverse process. *Masui* 41 : 111–118, 1992.

Seo K, Tanaka Y, Terumitsu M and Someya G. Efficacy of steroid

Treatment for sensory impairment after orthognathic surgery. J Oral
Maxillofac Surg 62 : 1193-1197, 2004.

Takeshige C and Sato M. Comparisons of pain relief mechanisms be-

tween needling to the muscle, static magnetic field, external qigong
and needling to the acupuncture point. Acupunct Electrother Res
21 : 119-131, 1996.